



Published in final edited form as:

Hippocampus. 2017 January ; 27(1): 3–11. doi:10.1002/hipo.22671.

A harmonized segmentation protocol for hippocampal and parahippocampal subregions: why do we need one and what are the key goals?

Laura E.M. Wisse^{#1}, Ana M. Daugherty^{#2}, Rosanna K. Olsen³, David Berron⁴, Valerie A. Carr^{5,6}, Craig E.L. Stark⁷, Robert S.C. Amaral^{8,9,10}, Katrin Amunts^{11,12,13}, Jean C. Augustinack¹⁴, Andrew R. Bender¹⁵, Jeffrey D. Bernstein¹⁶, Marina Boccardi¹⁷, Martina Bocchetta¹⁸, Alison Burggren¹⁹, M. Mallar Chakravarty^{8,9}, Marie Chupin²⁰, Arne Ekstrom^{21,22}, Robin de Flores²³, Ricardo Insausti²⁴, Prabesh Kanel²⁵, Olga Kedo¹¹, Kristen M. Kennedy²⁶, Geoffrey A. Kerchner¹⁶, Karen F. LaRocque⁵, Xiuwen Liu²⁵, Anne Maass²⁷, Nicolai Malykhin^{28,29,30}, Susanne G. Mueller^{31,32}, Noa Ofen^{33,34}, Daniela J. Palombo³⁵, Mansi B. Parekh³⁶, John B. Pluta¹, Jens C. Pruessner^{37,38}, Naftali Raz^{33,34}, Karen M. Rodrigue²⁶, Dorothee Schoemaker^{37,38}, Andrea T. Shafer^{33,34}, Trevor A. Steve³⁹, Nanthia Suthana^{19,40}, Lei Wang⁴¹, Julie L. Winterburn^{8,9}, Michael A. Yassa^{7,42}, Paul A. Yushkevich¹, Renaud la Joie²³, and the Hippocampal Subfields Group

¹Penn Image Computing and Science Laboratory, Department of Radiology, University of Pennsylvania, Philadelphia, USA ²Beckman Institute for Advanced Science and Technology, University of Illinois Urbana-Champaign, Champaign, USA ³Rotman Research Institute, Baycrest Health Sciences, Toronto, Ontario, Canada ⁴Institute of Cognitive Neurology and Dementia Research, Otto-von-Guericke University, Magdeburg, Germany ⁵Department of Psychology, Stanford University, Palo Alto, USA ⁶Department of Psychology, San Jose State University, San Jose, USA ⁷Department of Neurobiology and Behavior, University of California Irvine, Irvine, USA ⁸Cerebral Imaging Centre, Douglas Mental Health University Institute, McGill University, Montreal, Canada ⁹Departments of Psychiatry and Biological and Biomedical Engineering, McGill University, Montreal, Canada ¹⁰Integrated Program in Neuroscience, McGill University, Montreal, Canada ¹¹Institute of Neuroscience and Medicine, INM-1, Research Center Jülich, Jülich, Germany ¹²JARA-BRAIN, Jülich-Aachen Research Alliance, Jülich, Germany ¹³C. and O. Vogt Institute for Brain Research, Heinrich Heine University Düsseldorf, Düsseldorf, Germany ¹⁴AA Martinos Center for Biomedical Imaging, Department of Radiology, Harvard Medical School, Massachusetts General Hospital, Boston, USA ¹⁵Center for Lifespan Psychology, Max Planck Institute for Human Development, Berlin, Germany ¹⁶Department of Neurology and Neurological Sciences, Stanford University School of Medicine, Palo Alto, USA ¹⁷LANVIE Laboratory of Neuroimaging of Aging, University of Geneva, Geneva, Switzerland ¹⁸Dementia Research Centre, Department of Neurodegenerative Disease, UCL Institute of Neurology, Queen Square, London,

Corresponding author Laura E.M. Wisse, Richards Building 6th Floor, 3700 Hamilton Walk, PA 19104 Philadelphia, USA, Laura.Wisse@uphs.upenn.edu.

Disclosures

None of the authors has any disclosures, except GAK, who is an employee of Genentech, Inc.

See Supplementary Material for a list of collaborators in the Hippocampal Subfields Groups.

UK ¹⁹Department of Psychiatry and Biobehavioural Sciences, University of California Los Angeles, Los Angeles, USA ²⁰INSERM, CNRS, UMR-S975, Institut du Cerveau et de la Moelle Epinière (ICM), Paris, France. ²¹Center for Neuroscience, University of California Davis, Davis, USA ²²Department of Psychology, University of California Davis, Davis, USA ²³INSERM U1077, Université de Caen Normandie, UMR-S1077, Ecole Pratique des Hautes Etudes, Centre Hospitalier Universitaire de Caen, Caen, France ²⁴Human Neuroanatomy Laboratory and C.R.I.B., School of Medicine, University of Castilla-La Mancha, Albacete, Spain ²⁵Department of Computer Science, Florida State University, Tallahassee, USA ²⁶Center for Vital Longevity, School of Behavioral and Brain Sciences, University of Texas at Dallas, Dallas, USA ²⁷School of Public Health and Helen Wills Neuroscience Institute, University of California Berkeley, Berkeley, USA ²⁸Department of Biomedical Engineering, University of Alberta, Edmonton, Canada ²⁹The Neuroscience and Mental Health Institute, University of Alberta, Edmonton, Canada ³⁰Department of Psychiatry, University of Alberta, Edmonton, Canada ³¹Department of Radiology, University of California, San Francisco, USA ³²Center for Imaging of Neurodegenerative Diseases, San Francisco VA Medical Center, San Francisco, USA ³³Psychology Department, Wayne State University, Detroit, USA ³⁴Institute of Gerontology, Wayne State University, Detroit, USA ³⁵VA Boston Healthcare System, Boston, USA ³⁶Department of Radiology, Stanford University, Palo Alto, USA ³⁷McGill Centre for Studies in Aging, Faculty of Medicine, McGill University, Montreal, Canada ³⁸Department of Psychology, McGill University, Montreal, Canada ³⁹Division of Neurology, Department of Medicine, University of Alberta, Edmonton, Canada ⁴⁰Department of Neurosurgery, University of California Los Angeles, Los Angeles, USA ⁴¹Northwestern University Feinberg School of Medicine, Chicago, USA ⁴²Department of Neurology, University of California Irvine, Irvine, USA

These authors contributed equally to this work.

Abstract

The advent of high-resolution magnetic resonance imaging (MRI) has enabled *in vivo* research in a variety of populations and diseases on the structure and function of hippocampal subfields and subdivisions of the parahippocampal gyrus. Due to the many extant and highly discrepant segmentation protocols, comparing results across studies is difficult. To overcome this barrier, the Hippocampal Subfields Group was formed as an international collaboration with the aim of developing a harmonized protocol for manual segmentation of hippocampal and parahippocampal subregions on high-resolution MRI. In this commentary we discuss the goals for this protocol and the associated key challenges involved in its development. These include differences among existing anatomical reference materials, striking the right balance between reliability of measurements and anatomical validity, and the development of a versatile protocol that can be adopted for the study of populations varying in age and health. The commentary outlines these key challenges, as well as the proposed solution of each, with concrete examples from our working plan. Finally, with two examples, we illustrate how the harmonized protocol, once completed, is expected to impact the field by producing measurements that are quantitatively comparable across labs and by facilitating the synthesis of findings across different studies.

Keywords

Hippocampus; segmentation; harmonization; MRI; parahippocampal gyrus

Introduction

The medial temporal lobe (MTL) in general, and the hippocampus in particular, have attracted extensive interest in *in vivo* human studies of a wide range of diseases (e.g. (Small et al., 2011)), normal life-span development (e.g. (Daugherty et al., 2016)) and cognitive abilities (e.g. (Squire et al., 2004; Van Petten, 2004; Carr et al., 2010; Kyle et al., 2015a)) involving structural (e.g. (Mueller et al., 2008)) as well as functional magnetic resonance imaging (MRI) (e.g. (Yassa et al., 2010)). The MTL includes the hippocampal formation and several cortical regions within the parahippocampal gyrus, namely the entorhinal, perirhinal, and parahippocampal cortices. The hippocampal formation itself is a complex structure that is composed of distinct subfields—the subicular complex (including prosubiculum, subiculum proper, presubiculum and parasubiculum), Cornu ammonis (CA1-CA4), and the dentate gyrus (DG)¹ (e.g. (Duvernoy et al., 2005; Insausti and Amaral, 2012)). In the early 2000's, *in vivo* measurement of hippocampal subfields first became possible through advancements in neuroimaging and analysis techniques (Small et al., 1999; Small et al., 2000; Zeineh et al., 2000; Zeineh et al., 2001). Since then, over 20 manual protocols (e.g. (Insausti et al., 1998; Small et al., 1999; Zeineh et al., 2001; Kirwan et al., 2007; Mueller et al., 2007; Ekstrom et al., 2009; Olsen et al., 2009; Kerchner et al., 2010; La Joie et al., 2010; Malykhin et al., 2010; Preston et al., 2010; Yassa et al., 2010; Bonnici et al., 2012; Libby et al., 2012; Wisse et al., 2012; Bender et al., 2013; Palombo et al., 2013; Winterburn et al., 2013; Suthana et al., 2015); see also (Yushkevich et al., 2015a)) and several automatic procedures (e.g. (Fischl et al., 2009; Van Leemput et al., 2009; Yushkevich et al., 2010; Augustinack et al., 2013; Pipitone et al., 2014; Iglesias et al., 2015; Yushkevich et al., 2015b)) have been developed for *in vivo* segmentation on MR images of hippocampal and parahippocampal subregions. These manual and automatic segmentation protocols are highly discrepant from one another and often employ different terminology and definitions of the regional boundaries (Yushkevich et al., 2015a). This variability in segmentation protocols produces widely inconsistent results, even when studying similar populations and phenomena (e.g. (de Flores et al., 2015a; Wisse et al., 2015)). This variability complicates meaningful comparison of results between studies (de Flores et al., 2015a) and hampers the ability to draw broader theoretical conclusions. Thus, there is a strong need for a harmonized protocol that can be employed consistently across laboratories. Due to the wide variability in segmentation protocols and the lack of consensus in the field, no single protocol can be readily adopted as a common standard. Instead, it is necessary to develop a new manual segmentation protocol via consensus from the scientific community that resolves the various discrepancies and consolidates the commonalities across procedures and neuroanatomical reference sources. Although automated methods are appealing for efficiency and ease of

¹Note that the terminology for MTL structures differs per neuroanatomy laboratory. For example, some neuroanatomists prefer the term CA4 (Duvernoy et al., 2005), whereas others refer to this region as hilus (West and Gundersen, 1990) or part of CA3 (Insausti and Amaral, 2012).

adoption across research groups, the current automated protocols also differ widely from one another (Yushkevich et al., 2015a) and, when pitted against the “gold standard” of manual segmentation protocols, show limited concurrent validity, especially for smaller subfields. Automation of subfield segmentation therefore remains a hopeful future goal, but the first necessary step in its development is to establish a harmonized protocol for manual segmentation.

Inspired by the European Alzheimer's Disease Consortium (EADC) - Alzheimer's Disease Neuroimaging Initiative (ADNI) Harmonized Protocol (HarP) project (Boccardi et al., 2015; Frisoni et al., 2015), which successfully developed a reliable harmonized segmentation protocol for labeling the whole hippocampal formation as a single structure on 1 mm³ T1-weighted images, the Hippocampal Subfields Group (HSG) was formed in 2013 with the aim of developing a harmonized protocol for the segmentation of hippocampal subfields and the adjacent entorhinal, perirhinal and parahippocampal cortices (Kivisaari et al., 2013) for high-resolution T2-weighted 3 and 7 tesla (T) MRI data. T2-weighted imaging is the most commonly used for subfield segmentation because the stratum moleculare laconosum radiatum that is visualized as a “dark band” is used to separate the CA and the DG; this band is less visible on T1-weighted images. As one of the first steps towards harmonization, 21 segmentation protocols for hippocampal and parahippocampal subregions were compared directly and revealed a range of similarities and differences between protocols (Yushkevich et al., 2015a). The greatest disagreement between protocols in the hippocampal body, for example, was in the demarcation of the CA1-subicular complex boundary (see Figure 1). This comparison underscores the urgent need for a harmonized protocol.

Since publication of this comparison paper in 2015, the HSG has developed a working plan for creating a harmonized protocol for high-resolution T2-weighted MRIs. In short, it includes: 1) localizing subfield boundaries on histology in a reference set of multiple *ex vivo* specimens, 2) deriving specific rules for placing boundaries on *in vivo* MRI using this histological reference material, 3) sharing the protocol with the larger community to solicit feedback, and 4) performing a formal reliability analysis on the agreed manual segmentation protocol. These steps are illustrated in Figure 2. This working plan reflects three key goals: attaining content (anatomical) validity, establishing measurement reliability, and enabling application to study normative and pathological changes across the lifespan. These key goals are discussed below in the context of the unique challenges posed in this venture and the proposed working plan for achieving each goal. In addition, we elaborate on the expected impact of this harmonized protocol on the field.

Key goals and challenges in the development of a harmonized segmentation protocol for hippocampal and parahippocampal subregions

Content Validity: Agreement with Anatomy

The harmonized protocol must achieve content validity for anatomy confirmed by various histological reference materials. Although extant segmentation protocols adhere to printed neuroanatomical atlases (e.g. (Duvernoy et al., 2005; Mai et al., 2008; Insausti and Amaral, 2012)), they largely rely on different reference materials (Yushkevich et al., 2015a), which

may have, in part, contributed to the variability amongst protocols. In addition to simply providing different images and different anatomical definitions, most references depict a limited number of slices along the anterior-posterior length of the hippocampus. Furthermore, the angulation of histology samples commonly differs from the orientation of MRI, thereby limiting their usefulness as the anchors of validation. Moreover, printed anatomical atlases often show only a limited number of specimens, making approximation of individual differences in anatomical landmarks and variability of subfield boundaries along the anterior-posterior axis of the hippocampus difficult to assess.

Approach—To resolve the outlined challenges, at least three neuroanatomy laboratories (e.g. KA, RI & JCA) will provide a specimen, processed according to the standards in the specific labs, and all three labs will annotate each sample (Step 1)—thus creating a variety of samples whilst allowing direct comparison of anatomical boundary demarcation between neuroanatomists. Notably, subfield boundary placement may differ between neuroanatomists, potentially arising from differences in processing methods or their own subfield definitions. While resolving these potential discrepancies is beyond the scope of our effort, we will use all available information and characterize the range in which the boundaries may fall to develop a protocol for MRI. Moreover, the use of different processing methods will broaden the applicability of the harmonized protocol. Critically, the samples will include multiple slices spanning the anterior-posterior length and sectioning will be oriented similar to common neuroimaging protocols (i.e. perpendicular to the long axis of the hippocampus (Mueller et al., 2007; Yushkevich et al., 2015a)). This reference set will be the most comprehensive dataset to date and will be a good starting point, used in addition to canonical atlases, to develop a protocol for *in vivo* MRI segmentation. Although unique and comprehensive, this atlas set only includes 3 samples because of practical constraints—e.g., the labor intensive nature of annotating histological samples, the available time of the expert neuroanatomists and the availability of data either still intact or cut perpendicular to the long axis of the hippocampus, which is not a common neuroanatomical procedure. Therefore, existing histological references materials will also be used throughout the process and the neuroanatomists and MRI groups will continue to consult throughout the protocol development, particularly as it relates to individual differences in anatomical features.

Optimizing measurement reliability while maintaining anatomical validity

As important as the content validity vis-à-vis the anatomy is, the harmonized protocol must also produce reliable volumetric measures. High inter-rater reliability is particularly essential for this protocol as it is meant to be adopted and applied uniformly across groups. Because many of the features used to determine hippocampal subfield boundaries *ex vivo* (e.g., cell shape, size or density) cannot be visualized on high-resolution MRI, attempts to directly replicate anatomical boundaries commonly result in unreliable measures. An example is the endfolial pathway (Lim et al., 1997) in the stratum oriens of CA3, composed of loosely packed cells, which forms the inferior border of the CA3 curving into the DG. Although this border has been reported to be discernable on 7T MRI (Parekh et al., 2015), this border cannot be consistently observed on the typically-used lower-resolution 3T scans and might therefore lead to unreliable measurements. The use of a geometrical rule for this border on 3T data may therefore be necessary. Given the limitations of MRI resolution and

quality, some small compromises in neuroanatomical precision are to be expected as boundaries must be reliably reproduced. Thus, the HSG endeavors to create a protocol that strives to maximize the approximation of the MTL anatomy while affording high reliability of its measurement.

Approach—Toward this end, we will develop a manual segmentation protocol for T2-weighted MRI based on the comprehensive anatomical reference set, while testing reliability at multiple stages. In Step 2, we will derive heuristic rules from the anatomical reference set and, via comparison to MRI, determine landmarks available in the vast majority of *in vivo* T2-weighted MR images that are commonly used for hippocampal subfield segmentation. The draft protocol will be tested for reliability and may be subsequently re-tested until sufficient reliability is attained (Fig 2), based upon criteria reported in the literature and if needed, by majority voting. Additionally, following critical feedback from the larger community (Step 3), we will perform a formal reliability analysis of the final protocol in Step 4 with six raters drawn from across laboratories which will ensure that the protocol can be adopted by different research groups.

Broad application of the harmonized protocol

A final key goal is to develop a harmonized protocol that can be adopted widely for the study of populations across the lifespan and across several diseases. There are several practical challenges to achieving this goal: differences in scanning platform and acquisition protocols, variable scan quality (e.g., common motion artifacts in MRI scans of children or patients with Alzheimer's disease), segmentation goals of a particular study (e.g. the number of hippocampal subfields or cortical regions of interest) and potential differences in the hippocampal subfield boundary locations due to alterations in the internal composition of the hippocampus in certain populations.

Approach—We have incorporated a number of solutions in our working plan to ensure that the harmonized protocol meets the requirements and needs of different research groups. First, to allow for the highest level of adoption across research groups, we aim for the harmonized protocol to include definitions to separately segment the following subfields: subicular complex, CA1, CA2, CA3, and DG (including Fascia dentata and CA4), and the parahippocampal, perirhinal and entorhinal cortices. Such delineation will be contingent upon the achievement of high reliability and validity for each region. The protocol is intended to remain flexible for the user to decide which subfields to potentially collapse into a single measurement (e.g., the common inclusion of CA3 with the DG) depending on the particular research goals. Of note, we deliberately limit our protocol to the selected subfields in an effort to maintain high reliability of all measures, as the amount of detail on *in vivo* MR images is insufficient, in our opinion, to segment additional structures at 3T. Developing a protocol for 3T data is the first focus of the group as it is most common in the field. Upon completion of the 3T harmonized protocol, it will be adjusted for other applications, such as 7T structural images, which may involve adding more fine-grained demarcations to the 3T protocol.

Second, we will develop and test our protocol in two different datasets consisting of scans from different research groups and reflecting the different ages and diseases most commonly studied in relation to these MTL regions. More specifically, it will include the age range from 7-100 years, and scans from healthy subjects as well as patients with hypertension, epilepsy and Alzheimer's disease. Importantly, these images also reflect the different types of 3T scanner manufacturers and sequences used in the field, as well as commonly observed imaging artifacts. Relatedly, by using anatomical features that are observable on these MRI scans and rules that can fit hippocampi with varying shapes, the protocol will be able to accommodate variability in hippocampal morphometry that occurs in development and diseases such as epilepsy and Alzheimer's disease, as has been shown to be feasible by previous segmentation work in these populations (Mueller et al., 2010;Daugherty et al., 2016;Santyr et al., 2016). However, our MRI dataset does not include all possible MTL abnormalities that can occur due to injury or disease (e.g. encephalitis or prenatal/postnatal abnormalities that may affect the folding of the hippocampus (Rosenbaum et al., 2014)). We will therefore additionally leverage the collective experience of the large research community contributing to this effort, including members who have first-hand experience with segmentation in special cases of MTL abnormalities. Additionally, it should be noted that we currently only have access to histological material from older adults, but not to histological material from younger age groups or some of the diseases of interest in our effort. This may limit our ability to confirm anatomical validity of our protocol when applied to various pathological conditions that may plausibly alter the internal composition and shape of the hippocampus. When evaluating the validity of the protocol, we will therefore complement our histological dataset of healthy brains with histological reference material from pathology (e.g. (Insausti et al., 2010) whenever feasible. In the application to the study of development, we have a reasonable expectation that a similar protocol can be applied to samples of children and adults. Although hippocampal structure and morphometry continue to develop into adolescence (Insausti et al., 2010), the cytoarchitectonic differences that define the subfields as observed in the adult brain can be seen as early as mid-gestation (Humphrey, 1967;Arnold and Trojanowski, 1996) and are almost adult-like from the first postnatal year on (Insausti et al., 2010). Additionally, some cells in the hippocampal formation take on adult-like qualities between the 2nd and the 8th year (Seress et al., 2001;Seress, 2007). However, in the future, if more histological datasets become available with sectioning perpendicular to the long axis of the hippocampus, this may allow the validation of this protocol in younger age groups or certain disease populations and potentially necessitate updating the protocol.

Third, the HSG is a large, international collaborative group (approx. 150 members from more than 15 countries) that represents all levels of expertise and experience with different types of data, and different research interests. The HSG community will be asked for input in two stages. In Step 2, the boundary working group members (approx. 30) that are not involved in developing the *in vivo* definitions will be asked for initial feedback. In Step 3 feedback will be solicited from the larger community via an on-line questionnaire, similar to the Delphi procedure used in the HarP project (Boccardi et al., 2015). To further increase the versatility and expertise of the HSG, the authors invite other researchers to join this open effort and to provide input (www.hippocampalsubfields.com/mailing-list/).

Impact of a harmonized segmentation protocol for hippocampal and parahippocampal subregions

We expect that this harmonized protocol will have a significant impact in the research community as its use will enable direct comparison of results between studies, thereby better accommodating the replication of results and the pooling of data for meta-analyses. Existing data could potentially be reanalyzed with the harmonized protocol and we encourage researchers to consider this approach as an avenue for reconciling current discrepancies in the literature. Additionally, capitalizing on a uniform segmentation protocol adopted across research groups, the field can gain further insight into lifespan developmental trajectories and related diseases on hippocampal and parahippocampal structure and function. We provide two compelling examples of this in the study of aging and of pattern separation and completion for which the harmonized protocol could specifically be of added value.

Example 1: Age-related hippocampal subfield atrophy

Characterizing effects of advanced age on hippocampal subfield volumes is of great importance for understanding typical cognitive decline and departure from normal trajectories in the course of disease. Unfortunately, so far results pertaining to the association of age with hippocampal subfield volumes are inconclusive, with studies finding an effect of ageing on virtually all possible combinations of subfields (e.g. (Mueller and Weiner, 2009;Shing et al., 2011;Pereira et al., 2014;Wisse et al., 2014;de Flores et al., 2015b;Daugherty et al., 2016), for a review see (de Flores et al., 2015a)). These discrepancies most likely reflect, at least in part, differences between segmentation protocols. For example, the seemingly disparate findings of age differences in CA1 or subicular volume, might in fact pertain to the same region as these labels often overlap between segmentation protocols.

Hypothetically, new and existing data could be analyzed with the harmonized protocol and not only accommodate direct comparisons of age effects, but also evaluate differences in population characteristics and health (e.g., age-related decline in cardiovascular health (Shing et al., 2011;Bender et al., 2013)) that might account for variability among studies. In addition, a harmonized protocol will enable the synthesis and integration of results across studies that have included different age groups, thus allowing for a characterization of hippocampal volume across the lifespan without a single lab having to collect data from each age group.

Example 2: Pattern separation and completion

High-resolution fMRI studies of hippocampal subfields aim to elucidate their functional role across various cognitive tasks. Two important mechanisms thought to be involved in human memory and spatial navigation are pattern separation and pattern completion (Marr, 1971;McClelland et al., 1995;Yassa and Stark, 2011). Whereas it is proposed that pattern separation plays an important role whenever similar memories have to be encoded in a distinct fashion, pattern completion is critical for recalling episodes based on partial or degraded cues (Yassa et al., 2010;Hunsaker and Kesner, 2013). Anatomical evidence from non-human animal work, suggests that pattern separation relies on the DG (Leutgeb et al.,

2007), while pattern completion appears to be associated with a network of recurrent collaterals in CA3 (Neunuebel and Knierim, 2014).

So far, most human neuroimaging studies of pattern separation and completion mechanisms combine CA2, CA3 and DG into one region, due to limited spatial resolution currently available at 3T (e.g. (Bakker et al., 2008;Yassa et al., 2010;Dudukovic et al., 2011;Kyle et al., 2015b;Stokes et al., 2015)). With new technological advancements at 3T and increasing availability of high-resolution 7T imaging (Feinberg and Yacoub, 2012;Todd et al., 2016), it will become increasingly feasible to functionally separate these subregions. However, most extant segmentation protocols propose different locations of the CA3 boundaries and as a result variable numbers of CA3 voxels are counted towards DG (e.g. (Wisse et al., 2012;Winterburn et al., 2013;Iglesias et al., 2015;Yushkevich et al., 2015b)). This results in high anatomical variability in DG and CA3 masks among protocols. A harmonized protocol will therefore be critical to better understand the specific functional roles of DG and CA3 in pattern separation and completion using human *in vivo* imaging.

Summary

In summary, we are proposing to develop a harmonized segmentation protocol for *in vivo* T2-weighted MR images for hippocampal and parahippocampal subregions that maximally represent the underlying MTL anatomy while affording high reliability of its measurement and that can be applied in different study populations and on scans acquired in different research groups with different scanners. The development of this harmonized protocol for the currently available 3T and 7T data is crucial in the immediate future as the heterogeneity in protocols is greatly hampering progress of research related to these MTL regions. We believe the current plan will allow us to achieve our main aim of harmonization while also attaining acceptable anatomical validity. However, in the future, the protocol may be updated based upon advances in imaging and analysis techniques, as well as more comprehensive histology reference sets from different populations as they become available via ongoing research endeavors. Additionally, in the future, it would be helpful to obtain a common understanding of the parcellation at the microscopic scale, in which discrepancies in labeling are also an issue, e.g., with CA4 part of some histological segmentations but not others (e.g. (Duvernoy et al., 2005;Insausti and Amaral, 2012)).

We have started our effort by developing a manual segmentation protocol of the hippocampal subfields within the hippocampal body for T2-weighted 3T images because the body is included in all existing segmentation protocols (Yushkevich et al., 2015a) and is more uniform than the head and tail regions of the hippocampus. We plan to extend the protocol to the head and tail portions. We aim to finalize and publish the harmonized protocol for the hippocampal body in the near future to allow for its more immediate adoption while continuing the efforts for procedures in the remainder of the hippocampus, as well as the adjacent cortical regions.

To facilitate wide adoption of the harmonized protocol by new users, we plan to provide training resources, for example an instructional video or an example dataset, alongside the segmentation protocol. Additionally, we plan to implement it into (semi-)automated segmentation algorithms. All extant (semi-)automated segmentation procedures are atlas-

based and can be updated with the harmonized segmentation protocol. This step will therefore follow after the initial development of a manual harmonized segmentation protocol. When finished, this manual protocol will be made available to the research groups involved in the development of automated subfield segmentation algorithms (Pipitone et al., 2014; Iglesias et al., 2015; Yushkevich et al., 2015b), several of whom are part of this collaborative effort.

Supplementary Material

Refer to Web version on PubMed Central for supplementary material.

Acknowledgements

We thank the members of the larger Hippocampal Subfields Group for their input on the harmonization effort and insightful comments over the years. We acknowledge the work of Ms. Mercedes Iiguez de Onzo for magnificent technical work.

Funding sources

NR is supported in part by NIH grant R37 011230, ADE NIH/NINDS grant NS076856 and NS093052 and the UC Davis Chancellor's Award, TAS a post-graduate fellowship award from Eisai and the Canadian League Against Epilepsy (CLAE), AB by NIDA K01 DA034728, KMK by NIH/NIA R00 AG-036818, LW by Alzheimer Association grant ADNI 2-12-233036, RI by Grant GI20152980, MAY by US NIA P50 AG05146, NIA R21 AG049220, and NIMH R01 MH102392, MMC by National Sciences and Engineering Research Council Canada, Canadian Institutes of Health Research, Weston Brian Institute, Alzheimer's Association, Michael J. Fox Foundation for Parkinson's Research, and Fonds de recherche santé Québec and KMR by NIA R00 AG-36848, and PAY by NIA R01 AG037376 and NIBIB R01 EB017255, and RLJ by Fondation Thérèse et René Planiol pour l'étude du Cerveau

References

- Arnold SE, Trojanowski JQ. Human fetal hippocampal development: I. Cytoarchitecture, myeloarchitecture, and neuronal morphologic features. *J Comp Neurol.* 1996; 367:274–292. [PubMed: 8708010]
- Augustinack JC, Huber KE, Stevens AA, Roy M, Frosch MP, van der Kouwe AJ, Wald LL, Van Leemput K, McKee AC, Fischl B, Alzheimer's Disease Neuroimaging Initiative. Predicting the location of human perirhinal cortex, Brodmann's area 35, from MRI. *Neuroimage.* 2013; 64:32–42. [PubMed: 22960087]
- Bakker A, Kirwan CB, Miller M, Stark CE. Pattern separation in the human hippocampal CA3 and dentate gyrus. *Science.* 2008; 319:1640–1642. [PubMed: 18356518]
- Bender AR, Daugherty AM, Raz N. Vascular risk moderates associations between hippocampal subfield volumes and memory. *J Cogn Neurosci.* 2013; 25:1851–1862. [PubMed: 23767922]
- Boccardi M, Bocchetta M, Apostolova LG, Barnes J, Bartzokis G, Corbetta G, DeCarli C, deToledo-Morrell L, Firbank M, Ganzola R, Gerritsen L, Henneman W, Killiany RJ, Malykhin N, Pasqualetti P, Pruessner JC, Redolfi A, Robitaille N, Soininen H, Tolomeo D, Wang L, Watson C, Wolf H, Duvernoy H, Duchesne S, Jack CR Jr, Frisoni GB, EADC-ADNI Working Group on the Harmonized Protocol for Manual Hippocampal Segmentation. Delphi definition of the EADC-ADNI Harmonized Protocol for hippocampal segmentation on magnetic resonance. *Alzheimers Dement.* 2015; 11:126–138. [PubMed: 25130658]
- Bonnici HM, Chadwick MJ, Kumaran D, Hassabis D, Weiskopf N, Maguire EA. Multi-voxel pattern analysis in human hippocampal subfields. *Front Hum Neurosci.* 2012; 6:290. [PubMed: 23087638]
- Carr VA, Rissman J, Wagner AD. Imaging the human medial temporal lobe with high-resolution fMRI. *Neuron.* 2010; 65:298–308. [PubMed: 20159444]
- Daugherty AM, Bender AR, Raz N, Ofen N. Age differences in hippocampal subfield volumes from childhood to late adulthood. *Hippocampus.* 2016; 26:220–228. [PubMed: 26286891]

- de Flores R, La Joie R, Chetelat G. Structural imaging of hippocampal subfields in healthy aging and Alzheimer's disease. *Neuroscience*. 2015a; 309:29–50. [PubMed: 26306871]
- de Flores R, La Joie R, Landeau B, Perrotin A, Mezenge F, de La Sayette V, Eustache F, Desgranges B, Chetelat G. Effects of age and Alzheimer's disease on hippocampal subfields: comparison between manual and FreeSurfer volumetry. *Hum Brain Mapp*. 2015b; 36:463–474. [PubMed: 25231681]
- Dudukovic NM, Preston AR, Archie JJ, Glover GH, Wagner AD. High-resolution fMRI reveals match enhancement and attentional modulation in the human medial temporal lobe. *J Cogn Neurosci*. 2011; 23:670–682. [PubMed: 20433244]
- Duvernoy, HM.; Cattin, E.; Naidich, T.; Fatterpekar, GM.; Raybaud, C.; Risold, PY.; Sakvolini, U.; Scarabino, T. *The human hippocampus*. Springer Verlag Berlin Heidelberg; Germany: 2005. p. 1-232.
- Ekstrom AD, Bazih AJ, Suthana NA, Al-Hakim R, Ogura K, Zeineh M, Burggren AC, Bookheimer SY. Advances in high-resolution imaging and computational unfolding of the human hippocampus. *Neuroimage*. 2009; 47:42–49. [PubMed: 19303448]
- Feinberg DA, Yacoub E. The rapid development of high speed, resolution and precision in fMRI. *Neuroimage*. 2012; 62:720–725. [PubMed: 22281677]
- Fischl B, Stevens AA, Rajendran N, Yeo BT, Greve DN, Van Leemput K, Polimeni JR, Kakunoori S, Buckner RL, Pacheco J, Salat DH, Melcher J, Frosch MP, Hyman BT, Grant PE, Rosen BR, van der Kouwe AJ, Wiggins GC, Wald LL, Augustinack JC. Predicting the location of entorhinal cortex from MRI. *Neuroimage*. 2009; 47:8–17. [PubMed: 19376238]
- Frisoni GB, Jack CR Jr, Bocchetta M, Bauer C, Frederiksen KS, Liu Y, Preboske G, Swihart T, Blair M, Cavado E, Grothe MJ, Lanfredi M, Martinez O, Nishikawa M, Portegies M, Stoub T, Ward C, Apostolova LG, Ganzola R, Wolf D, Barkhof F, Bartzokis G, DeCarli C, Csernansky JG, deToledo-Morrell L, Geerlings MI, Kaye J, Killiany RJ, Lehericy S, Matsuda H, O'Brien J, Silbert LC, Scheltens P, Soinen H, Teipel S, Waldemar G, Fellgiebel A, Barnes J, Firbank M, Gerritsen L, Henneman W, Malykhin N, Pruessner JC, Wang L, Watson C, Wolf H, deLeon M, Pantel J, Ferrari C, Bosco P, Pasqualetti P, Duchesne S, Duvernoy H, Boccardi M, EADC-ADNI Working Group on The Harmonized Protocol for Manual Hippocampal Volumetry and for the Alzheimer's Disease Neuroimaging Initiative. The EADC-ADNI Harmonized Protocol for manual hippocampal segmentation on magnetic resonance: evidence of validity. *Alzheimers Dement*. 2015; 11:111–125. [PubMed: 25267715]
- Humphrey T. The development of the human hippocampal fissure. *J Anat*. 1967; 101:655–676. [PubMed: 6059818]
- Hunsaker MR, Kesner RP. The operation of pattern separation and pattern completion processes associated with different attributes or domains of memory. *Neurosci Biobehav Rev*. 2013; 37:36–58. [PubMed: 23043857]
- Iglesias JE, Augustinack JC, Nguyen K, Player CM, Player A, Wright M, Roy N, Frosch MP, McKee AC, Wald LL, Fischl B, Van Leemput K, Alzheimer's Disease Neuroimaging Initiative. A computational atlas of the hippocampal formation using ex vivo, ultra-high resolution MRI: Application to adaptive segmentation of in vivo MRI. *Neuroimage*. 2015; 115:117–137. [PubMed: 25936807]
- Insausti, R.; Cebaza-Sanchez, S.; Marcos, P. *Postnatal development of the human hippocampal formation*. Springer; Frankfurt: 2010.
- Insausti, R.; Amaral, DG. *Hippocampal formation*. Mai, JK.; Paxinos, G., editors. Elsevier Academic Press; San Diego: 2012.
- Insausti R, Juottonen K, Soinen H, Insausti AM, Partanen K, Vainio P, Laakso MP, Pitkanen A. MR volumetric analysis of the human entorhinal, perirhinal, and temporopolar cortices. *AJNR Am J Neuroradiol*. 1998; 19:659–671. [PubMed: 9576651]
- Kerchner GA, Hess CP, Hammond-Rosenbluth KE, Xu D, Rabinovici GD, Kelley DA, Vigneron DB, Nelson SJ, Miller BL. Hippocampal CA1 apical neuropil atrophy in mild Alzheimer disease visualized with 7-T MRI. *Neurology*. 2010; 75:1381–1387. [PubMed: 20938031]
- Kirwan CB, Jones CK, Miller MI, Stark CE. High-resolution fMRI investigation of the medial temporal lobe. *Hum Brain Mapp*. 2007; 28:959–966. [PubMed: 17133381]

- Kivisaari, SL.; Probst, A.; Taylor, KI. The Perirhinal, Entorhinal, and Parahippocampal Cortices and Hippocampus: An Overview of Functional Anatomy and Protocol for Their Segmentation in MR Images. Ulmer, S.; Jansen, O., editors. Springer-Verlag; Berlin Heidelberg: 2013. p. 239
- Kyle CT, Smuda DN, Hassan AS, Ekstrom AD. Roles of human hippocampal subfields in retrieval of spatial and temporal context. *Behav Brain Res*. 2015a; 278:549–558. [PubMed: 25446813]
- Kyle CT, Stokes JD, Lieberman JS, Hassan AS, Ekstrom AD. Successful retrieval of competing spatial environments in humans involves hippocampal pattern separation mechanisms. *Elife*. 2015b; 4:10.7554/eLife.10499.
- La Joie R, Fouquet M, Mezenge F, Landeau B, Villain N, Mevel K, Pelerin A, Eustache F, Desgranges B, Chetelat G. Differential effect of age on hippocampal subfields assessed using a new high-resolution 3T MR sequence. *Neuroimage*. 2010; 53:506–514. [PubMed: 20600996]
- Leutgeb JK, Leutgeb S, Moser MB, Moser EI. Pattern separation in the dentate gyrus and CA3 of the hippocampus. *Science*. 2007; 315:961–966. [PubMed: 17303747]
- Libby LA, Ekstrom AD, Ragland JD, Ranganath C. Differential connectivity of perirhinal and parahippocampal cortices within human hippocampal subregions revealed by high-resolution functional imaging. *J Neurosci*. 2012; 32:6550–6560. [PubMed: 22573677]
- Lim C, Mufson EJ, Kordower JH, Blume HW, Madsen JR, Saper CB. Connections of the hippocampal formation in humans: II. The endfolial fiber pathway. *J Comp Neurol*. 1997; 385:352–371. [PubMed: 9300764]
- Mai, JK.; Paxinos, G.; Voss, T. Atlas of the human brain. Academic Press, Elsevier; New York, USA: 2008. p. 1-271.
- Malykhin NV, Lebel RM, Coupland NJ, Wilman AH, Carter R. In vivo quantification of hippocampal subfields using 4.7 T fast spin echo imaging. *Neuroimage*. 2010; 49:1224–1230. [PubMed: 19786104]
- Marr D. Simple memory: a theory for archicortex. *Philos Trans R Soc Lond B Biol Sci*. 1971; 262:23–81. [PubMed: 4399412]
- McClelland JL, McNaughton BL, O'Reilly RC. Why there are complementary learning systems in the hippocampus and neocortex: insights from the successes and failures of connectionist models of learning and memory. *Psychol Rev*. 1995; 102:419–457. [PubMed: 7624455]
- Mueller SG, Schuff N, Yaffe K, Madison C, Miller B, Weiner MW. Hippocampal atrophy patterns in mild cognitive impairment and Alzheimer's disease. *Hum Brain Mapp*. 2010; 31:1339–1347. [PubMed: 20839293]
- Mueller SG, Weiner MW. Selective effect of age, Apo e4, and Alzheimer's disease on hippocampal subfields. *Hippocampus*. 2009; 19:558–564. [PubMed: 19405132]
- Mueller SG, Schuff N, Raptentsetsang S, Elman J, Weiner MW. Selective effect of Apo e4 on CA3 and dentate in normal aging and Alzheimer's disease using high resolution MRI at 4 T. *Neuroimage*. 2008; 42:42–48. [PubMed: 18534867]
- Mueller SG, Stables L, Du AT, Schuff N, Truran D, Cashdollar N, Weiner MW. Measurement of hippocampal subfields and age-related changes with high resolution MRI at 4T. *Neurobiol Aging*. 2007; 28:719–726. [PubMed: 16713659]
- Neunuebel JP, Knierim JJ. CA3 retrieves coherent representations from degraded input: direct evidence for CA3 pattern completion and dentate gyrus pattern separation. *Neuron*. 2014; 81:416–427. [PubMed: 24462102]
- Olsen RK, Nichols EA, Chen J, Hunt JF, Glover GH, Gabrieli JD, Wagner AD. Performance-related sustained and anticipatory activity in human medial temporal lobe during delayed match-to-sample. *J Neurosci*. 2009; 29:11880–11890. [PubMed: 19776274]
- Palombo DJ, Amaral RS, Olsen RK, Muller DJ, Todd RM, Anderson AK, Levine B. KIBRA polymorphism is associated with individual differences in hippocampal subregions: evidence from anatomical segmentation using high-resolution MRI. *J Neurosci*. 2013; 33:13088–13093. [PubMed: 23926262]
- Parekh MB, Rutt BK, Purcell R, Chen Y, Zeineh MM. Ultra-high resolution in-vivo 7.0T structural imaging of the human hippocampus reveals the endfolial pathway. *Neuroimage*. 2015; 112:1–6. [PubMed: 25701699]

- Pereira JB, Valls-Pedret C, Ros E, Palacios E, Falcon C, Bargallo N, Bartres-Faz D, Wahlund LO, Westman E, Junque C. Regional vulnerability of hippocampal subfields to aging measured by structural and diffusion MRI. *Hippocampus*. 2014; 24:403–414. [PubMed: 24339261]
- Pipitone J, Park MT, Winterburn J, Lett TA, Lerch JP, Pruessner JC, Lepage M, Voineskos AN, Chakravarty MM, Alzheimer's Disease Neuroimaging Initiative. Multi-atlas segmentation of the whole hippocampus and subfields using multiple automatically generated templates. *Neuroimage*. 2014; 101:494–512. [PubMed: 24784800]
- Preston AR, Bornstein AM, Hutchinson JB, Gaare ME, Glover GH, Wagner AD. High-resolution fMRI of content-sensitive subsequent memory responses in human medial temporal lobe. *J Cogn Neurosci*. 2010; 22:156–173. [PubMed: 19199423]
- Rosenbaum RS, Gao F, Honjo K, Raybaud C, Olsen RK, Palombo DJ, Levine B, Black SE. Congenital absence of the mammillary bodies: a novel finding in a well-studied case of developmental amnesia. *Neuropsychologia*. 2014; 65:82–87. [PubMed: 25301386]
- Santyr BG, Goubran M, Lau JC, Kwan BY, Salehi F, Lee DH, Mirsattari SM, Burneo JG, Steven DA, Parrent AG, de Ribaupierre S, Hammond RR, Peters TM, Khan AR. Investigation of hippocampal substructures in focal temporal lobe epilepsy with and without hippocampal sclerosis at 7T. *J Magn Reson Imaging*. 2016
- Seress L. Comparative anatomy of the hippocampal dentate gyrus in adult and developing rodents, non-human primates and humans. *Prog Brain Res*. 2007; 163:23–41. [PubMed: 17765710]
- Seress L, Abraham H, Tornoczky T, Kosztolanyi G. Cell formation in the human hippocampal formation from mid-gestation to the late postnatal period. *Neuroscience*. 2001; 105:831–843. [PubMed: 11530221]
- Shing YL, Rodrigue KM, Kennedy KM, Fandakova Y, Bodammer N, Werkle-Bergner M, Lindenberger U, Raz N. Hippocampal subfield volumes: age, vascular risk, and correlation with associative memory. *Front Aging Neurosci*. 2011; 3:2. [PubMed: 21331174]
- Small SA, Schobel SA, Buxton RB, Witter MP, Barnes CA. A pathophysiological framework of hippocampal dysfunction in ageing and disease. *Nat Rev Neurosci*. 2011; 12:585–601. [PubMed: 21897434]
- Small SA, Wu EX, Bartsch D, Perera GM, Lacefield CO, DeLaPaz R, Mayeux R, Stern Y, Kandel ER. Imaging physiologic dysfunction of individual hippocampal subregions in humans and genetically modified mice. *Neuron*. 2000; 28:653–664. [PubMed: 11163257]
- Small SA, Perera GM, DeLaPaz R, Mayeux R, Stern Y. Differential regional dysfunction of the hippocampal formation among elderly with memory decline and Alzheimer's disease. *Ann Neurol*. 1999; 45:466–472. [PubMed: 10211471]
- Squire LR, Stark CE, Clark RE. The medial temporal lobe. *Annu Rev Neurosci*. 2004; 27:279–306. [PubMed: 15217334]
- Stokes J, Kyle C, Ekstrom AD. Complementary roles of human hippocampal subfields in differentiation and integration of spatial context. *J Cogn Neurosci*. 2015; 27:546–559. [PubMed: 25269116]
- Suthana NA, Donix M, Wozny DR, Bazih A, Jones M, Heidemann RM, Trampel R, Ekstrom AD, Scharf M, Knowlton B, Turner R, Bookheimer SY. High-resolution 7T fMRI of Human Hippocampal Subfields during Associative Learning. *J Cogn Neurosci*. 2015; 27:1194–1206. [PubMed: 25514656]
- Todd N, Moeller S, Auerbach EJ, Yacoub E, Flandin G, Weiskopf N. Evaluation of 2D multiband EPI imaging for high-resolution, whole-brain, task-based fMRI studies at 3T: Sensitivity and slice leakage artifacts. *Neuroimage*. 2016; 124:32–42. [PubMed: 26341029]
- Van Leemput K, Bakkour A, Benner T, Wiggins G, Wald LL, Augustinack J, Dickerson BC, Golland P, Fischl B. Automated segmentation of hippocampal subfields from ultra-high resolution in vivo MRI. *Hippocampus*. 2009; 19:549–557. [PubMed: 19405131]
- Van Petten C. Relationship between hippocampal volume and memory ability in healthy individuals across the lifespan: review and meta-analysis. *Neuropsychologia*. 2004; 42:1394–1413. [PubMed: 15193947]
- West MJ, Gundersen HJ. Unbiased stereological estimation of the number of neurons in the human hippocampus. *J Comp Neurol*. 1990; 296:1–22. [PubMed: 2358525]

- Winterburn JL, Pruessner JC, Chavez S, Schira MM, Lobaugh NJ, Voineskos AN, Chakravarty MM. A novel in vivo atlas of human hippocampal subfields using high-resolution 3 T magnetic resonance imaging. *Neuroimage*. 2013; 74:254–265. [PubMed: 23415948]
- Wisse LE, Biessels GJ, Stegenga BT, Kooistra M, van der Veen PH, Zwanenburg JJ, van der Graaf Y, Geerlings MI. Major depressive episodes over the course of 7 years and hippocampal subfield volumes at 7 tesla MRI: the PREDICT-MR study. *J Affect Disord*. 2015; 175:1–7. [PubMed: 25589378]
- Wisse LE, Biessels GJ, Heringa SM, Kuijf HJ, Koek DH, Luijten PR, Geerlings MI, Utrecht Vascular Cognitive Impairment (VCI) Study Group. Hippocampal subfield volumes at 7T in early Alzheimer's disease and normal aging. *Neurobiol Aging*. 2014; 35:2039–2045. [PubMed: 24684788]
- Wisse LEM, Gerritsen L, Zwanenburg JJ, Kuijf HJ, Luijten PR, Biessels GJ, Geerlings MI. Subfields of the hippocampal formation at 7 T MRI: in vivo volumetric assessment. *Neuroimage*. 2012; 61:1043–1049. [PubMed: 22440643]
- Yassa MA, Stark CE. Pattern separation in the hippocampus. *Trends Neurosci*. 2011; 34:515–525. [PubMed: 21788086]
- Yassa MA, Stark SM, Bakker A, Albert MS, Gallagher M, Stark CE. High-resolution structural and functional MRI of hippocampal CA3 and dentate gyrus in patients with amnesic Mild Cognitive Impairment. *Neuroimage*. 2010; 51:1242–1252. [PubMed: 20338246]
- Yushkevich PA, Amaral RS, Augustinack JC, Bender AR, Bernstein JD, Boccardi M, Bocchetta M, Burggren AC, Carr VA, Chakravarty MM, Chetelat G, Daugherty AM, Davachi L, Ding SL, Ekstrom A, Geerlings MI, Hassan A, Huang Y, Iglesias JE, La Joie R, Kerchner GA, LaRocque KF, Libby LA, Malykhin N, Mueller SG, Olsen RK, Palombo DJ, Parekh MB, Pluta JB, Preston AR, Pruessner JC, Ranganath C, Raz N, Schlichting ML, Schoemaker D, Singh S, Stark CE, Suthana N, Tompariy A, Turowski MM, Van Leemput K, Wagner AD, Wang L, Winterburn JL, Wisse LE, Yassa MA, Zeineh MM, Hippocampal Subfields Group (HSG). Quantitative comparison of 21 protocols for labeling hippocampal subfields and parahippocampal subregions in in vivo MRI: Towards a harmonized segmentation protocol. *Neuroimage*. 2015a
- Yushkevich PA, Pluta JB, Wang H, Xie L, Ding SL, Gertje EC, Mancuso L, Kliot D, Das SR, Wolk DA. Automated volumetry and regional thickness analysis of hippocampal subfields and medial temporal cortical structures in mild cognitive impairment. *Hum Brain Mapp*. 2015b; 36:258–287. [PubMed: 25181316]
- Yushkevich PA, Wang H, Pluta J, Das SR, Craige C, Avants BB, Weiner MW, Mueller S. Nearly automatic segmentation of hippocampal subfields in in vivo focal T2-weighted MRI. *Neuroimage*. 2010; 53:1208–1224. [PubMed: 20600984]
- Zeineh MM, Engel SA, Thompson PM, Bookheimer SY. Unfolding the human hippocampus with high resolution structural and functional MRI. *Anat Rec*. 2001; 265:111–120. [PubMed: 11323773]
- Zeineh MM, Engel SA, Bookheimer SY. Application of cortical unfolding techniques to functional MRI of the human hippocampal region. *Neuroimage*. 2000; 11:668–683. [PubMed: 10860795]




Figure 1. Comparison of 21 segmentation protocols in a coronal section in the hippocampal body of one subject. Figure from Yushkevich et al, NeuroImage, 2016; reprinted with permission from Elsevier.
 Alv=Alveus; CA=Cornu ammonis; CSF=Cerebrospinal fluid; DG=Dentate gyrus; DG:H=Dentate gyrus Hilar region; Fim=Fimbria; GCL=Granular cell layer; H=Hippocampus; Para=Parasubiculum; PHC=Parahippocampal cortex; Pre=Presubiculum; Sub=Subiculum; SP=Stratum pyramidale; SRLM=Stratum Radiatum Lacunosum Moleculare

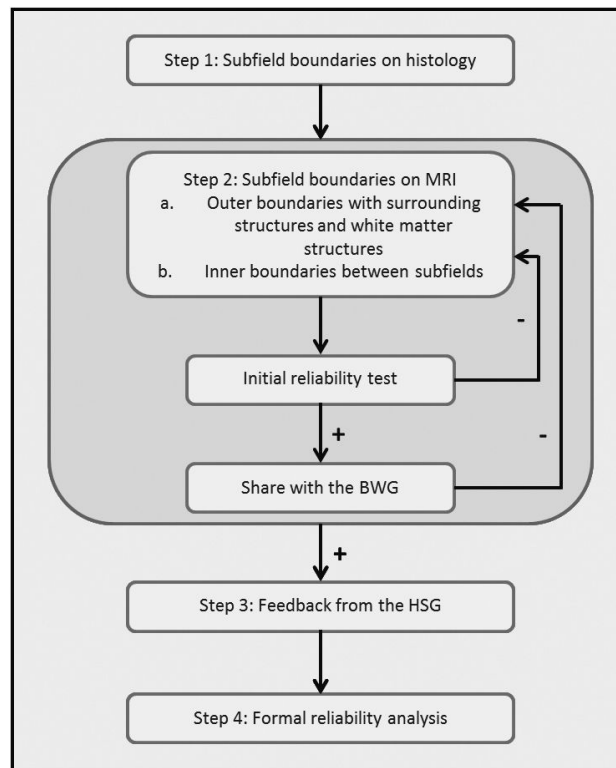


Figure 2.

Overview of the concrete steps involved in the harmonization project. In Step 1 in a set of three tissue samples, the boundaries on histology will be annotated by three anatomists. In Step 2 the boundaries on MRI will be derived based on the anatomical reference set in Step 1. The set boundaries are divided into two sets: the outer boundaries with surrounding structures and the boundaries between the subfields. Note for Step 2 that for both protocols an initial reliability test will be performed and the protocols will be shared with the Boundary Working Group (BWG). In case the reliability criteria are not met or in case of considerable critique, the protocol will be adjusted. This will be an iterative process. In Step 3 feedback will be elicited from the larger Hippocampal Subfields Group (HSG). In Step 4 a formal reliability analysis will be performed by six raters from different labs.